

Efficacy of Clonidine as an Adjuvant to Ropivacaine in Ultrasound guided Supraclavicular Brachial Plexus Block: A Prospective Study

Sarvesh. B¹, Prajwal Patel HS², Shivaramu BT³

¹Assistant Professor, ^{2,3}Associate Professor, Department of anesthesiology, Adichunchanagiri Institute of Medical Sciences, Mandya, Karnataka 571448, India.

Abstract

Background and Aims: Supraclavicular brachial plexus block provides rapid onset and more consistent regional anesthesia, as compared to other approaches. We hypothesized that addition of clonidine to ropivacaine in ultrasound guided supraclavicular brachial plexus block will enhance the quality of analgesia and prolong the duration of postoperative analgesia in patients undergoing upper limb surgeries. **Methods:** This study included 100 patients posted for upper limb surgeries who were randomly allocated into 2 groups of 50 each. Group R patients were given 19 ml of 0.75% ropivacaine + 1 ml normal saline and Group RC were given 19 ml of 0.75% ropivacaine with 0.5 µg/kg clonidine in 1 ml NS. Chi-square test was used to analyse categorical data and student's t-test was used to analyse quantitative data. **Results:** The onset of sensorimotor block was earlier in Group RC (4.03 ± 0.18 min for sensory block and 9.18 ± 0.11 min for motor block) than in Group R (5.23 ± 0.18 min for sensory block and 11.37 ± 0.44 min for motor block). Both sensory and motor block duration were significantly prolonged by clonidine (p value < 0.0001). The duration of analgesia was also prolonged in Group RC 848.31 ± 5.59 as compared to Group R 596.12 ± 3.79 (p < 0.0001). None of the patients in either group observed any adverse effects. **Conclusion:** Addition of Clonidine to ropivacaine in supraclavicular brachial plexus block results in faster onset and prolonged duration of sensory, motor blockade and postoperative analgesia without any significant adverse effects.

Keywords: Ultrasound; Clonidine; ropivacaine 0.75%; supraclavicular brachial plexus block.

How to cite this article:

Sarvesh. B, Prajwal Patel HS, Shivaramu BT. Efficacy of Clonidine as an Adjuvant to Ropivacaine in Ultrasound guided Supraclavicular Brachial Plexus Block: A Prospective Study. Indian J Anesth Analg. 2019;6(2):632-638.

Introduction

Peripheral nerve blocks provide adequate intraoperative anesthesia and also prolong the postoperative analgesia without any significant adverse effects [1]. And at the same time they are cost effective as compared to general anesthesia. The brachial plexus block is highly useful and safe technique for upper limb surgery under regional

anaesthesia [2]. The supraclavicular brachial plexus block provides anaesthesia for entire upper extremity below the shoulder in most consistent manner, as compared with other approaches to brachial plexus block.

Several local anesthetics have been used in brachial plexus block. Ropivacaine is a long acting amino amide local anaesthetic drug prepared as a pure S(-) enantiomer. Being less lipophilic than

Corresponding Author: Prajwal Patel H.S, Associate Professor, Department of anesthesiology, Adichunchanagiri Institute of Medical Sciences, Mandya, Karnataka 571448, India.

E-mail: drsarveshb83@gmail.com

Received on 11.01.2019, **Accepted on** 02.02.2019

bupivacaine, ropivacaine is less likely to penetrate large myelinated motor fibres ($A\beta$), resulting in a comparatively less intense motor blockade [3]. It has lesser cardiotoxicity and arrhythmogenicity than bupivacaine [4].

Various adjuvants have been used to enhance efficacy of brachial plexus block like opioids, midazolam, neostigmine, bicarbonate, hyaluronidase and α -2 agonists [5]. Clonidine, an imidazoline is a selective α -2 adrenergic agonist with certain α -1 agonist property. Clonidine has been used since several years as a centrally acting antihypertensive agent and has also been used as an adjunct with ropivacaine for epidural anaesthesia [6,7]. Clonidine, as an adjuvant to local anaesthetic agent, has been reported to extend the duration of peripheral nerve block [8]. Administration of α -2 adrenergic agonist drugs as adjuvants to local anesthetics enhances their action through either local α -2 mediated vasoconstriction and facilitation of C fiber blockade, spinal action caused by retrograde axonal transport or simple diffusion along the nerve, centrally mediated analgesia and antiinflammatory activity and direct action on peripheral nerve [9,10].

Ultrasound-guided regional anaesthesia as an edge over other nerve localization techniques, because it has an added advantage of dynamic visualization of the relevant anatomical structures and needle tip along with visibility of local anaesthetic spread in real time. Now there is a level 1b evidence available which states that ultrasound-guidance improves both the quality and the speed of onset of peripheral nerve blocks [11]. Ultrasound guidance can also aid in reduction of local anesthetic drug volume and complications.

The aim of the present study was to study the effects of clonidine as an adjuvant with ropivacaine on peripheral nerves during ultrasound guided supraclavicular brachial plexus block in term of its speed of onset, duration, degree of sensory/motor blockade, post-operative analgesia and to detect any potential adverse effects.

Materials and Methods

After obtaining approval from institutional ethical committee a prospective, randomized, double-blinded study was carried out on 100 ASA physical status I and II patients of either sex, aged 18-60 years undergoing various orthopaedic surgeries on the upper extremities distal to shoulder under ultrasound guided supraclavicular brachial plexus block. 100 patients were divided

into two groups of fifty patients each. The study was conducted in two groups of 50 patients each between June 2017 and August 2018. Patients were randomly allotted to two groups by computer-generated random selection. Group R patients received ropivacaine 0.75% (19 ml) and placebo (1 ml NS) whereas Group RC patients received ropivacaine 0.75% (19 ml) and clonidine 0.5 μ g/kg diluted in 1 ml NS. Randomization and preparation of injecting drugs were done by an anesthesiologist who was not an investigator and it was concealed from patients and investigators until completion of statistical analysis. The exclusion criteria of our study were patient refusal, patients suffering from chronic pain and on long term analgesics, coagulation disorders, history of brachial plexus injury, known allergy to any of the study drugs, patients on α -adrenergic blockers, severe hepatic or renal insufficiency, sepsis or active infection at the site of injection. Patients were familiarized pre-operatively about the usage of visual analogue scale for assessment of pain. A detailed pre anesthetic assessment was done on previous day of surgery and all the patients were kept NPO for 8 hours. The nature and safety of the procedure was explained to all patients in their own language and written, valid, informed consent obtained.

After arrival in the operation theatre, baseline blood pressure, pulse rate and oxygen saturation, ECG was recorded. An 18G intravenous (iv) cannula was secured and Ringer lactate fluid was started. All patients were given 0.01 mg/kg of iv midazolam as premedication before giving block. The patients were made to lie down in supine position with arms kept by the side and head tilted 45° to the opposite side. GE Voluson E with GE 12L-RS linear high frequency probe was used to perform all the blocks. A preliminary scan was done in supraclavicular fossa to study the anatomy and identify the desired needle path. With all aseptic precaution the proposed block site was painted with betadine and draped with sterile sheets. Ultrasound probe wire was covered with sterile sleeve and probe was covered with sterile tegaderm. After applying sterile gel, the transducer was positioned in coronal oblique plane over supraclavicular fossa. A cross-sectional view of the subclavian artery was obtained by tilting the transducer caudally. The supraclavicular brachial plexus seen as a collection of hypoechoic grape like structures lateral and superior to the artery. First rib and pleura were visualized as linear hyper echoic structures below the subclavian artery. After obtaining a proper image, 2 mL of 1% lignocaine was injected into the skin 1 cm lateral to the probe

to reduce the pain during block needle insertion. A 5 cm 22G insulated block needle was inserted in-plane toward the ulnar pocket of brachial plexus from lateral-to-medial direction. After careful aspiration, 1 mL of local anesthetic was injected to confirm the proper needle placement. After confirming proper needle tip placement in ulnar pocket 7 ml of drug was injected incrementally with careful negative aspiration. Block needle was repositioned laterally and superiorly under continuous vision and remaining local anesthetic was injected incrementally after careful negative aspiration to result in complete spread of local anesthetic drug in and around the brachial plexus.

Sensory blockade was assessed every minute and motor block was evaluated at 2 min intervals for the initial 30 min following completion of block procedure. Sensory block was tested by pinprick method using a 23G needle in dermatomes innervated by the nerves of brachial plexus (C5-T1) such as, median nerve, ulnar nerve, radial nerve and musculocutaneous nerve until complete sensory blockade. A dull sensation to pin prick along the distribution of any of these nerves was taken as sensory onset time. Complete loss of sensation to pin prick was considered as complete sensory block. Sensory block was graded as: 1) Grade 0 when sharp pain felt, 2) Grade 1 when blunt sensation felt and 3) Grade 2 complete anesthesia and no sensation felt.

Assessment of motor block was carried out by the same observer every two minute until complete motor blockade after block completion using modified bromage score. Motor blockade was evaluated as: 1) Grade 0- able to raise the extended arm to 90 degree for a full 2 second. 2) Grade 1- able to flex the elbow and move the fingers but unable to raise the extended arm. 3) Unable to flex the elbow but able to move the fingers. 4) Unable to move the arm, elbow or fingers. The time when the muscle power was reduced to Grade 3 or less was considered as motor onset time. Complete inability to move the limb and fingers (Grade 0) was considered as complete motor block. None of the blocks were failed.

Intra-operative blood loss was assessed and fluids administered accordingly.

All patients were meticulously monitored and observed for any adverse effects like nausea, vomiting, dryness of mouth, sedation, hypotension, bradycardia and complications like pneumothorax, hematoma, local anesthetic toxicity and post procedural neuropathy in the intra- and post-operative periods. Any medications administered were also noted.

After completion of surgery, all patients were monitored in post anesthesia care unit and received rescue analgesic (Tramadol 2 µg/kg slow IV) on demand and that time of first request for postoperative rescue analgesic was recorded in each patient. The duration of sensory block was defined as the time interval between completion of block procedure and complete recovery of sensation. The duration of motor block was defined as the time interval between completion of block procedure and complete recovery of motor power.

Duration of analgesia was the primary outcome measure where as onset and duration of sensory blockade, VAS pain scores, onset and duration of motor blockade and adverse drug reactions were secondary outcome measures.

Results

The demographic profile and the baseline values of vital parameters were statistically comparable between the two groups [Table 1].

The mean time of onset of sensory block in Group R was 5.23 ± 0.18 min and in Group RC was 4.03 ± 0.09 min ($p < 0.00001$) [Fig. 1]. The mean time of onset of motor block in Group R was 11.37 ± 0.44 min and in Group RC was 9.18 ± 0.11 min ($P < 0.00001$) [Fig. 1]. The mean duration of sensory block in Group R was 550.53 ± 2.85 min and in Group RC was 694.53 ± 2.95 min ($P < 0.00001$) [Fig. 2]. The mean duration of motor block in Group R was 499.54 ± 2.89 min and in Group RC was 612.04 ± 4.73 min ($P < 0.00001$) [Fig. 2]. The mean duration of analgesia in Group R was 596.12 ± 3.79 min and in Group RC was 848.31 ± 5.59 min ($p < 0.00001$) (Figure 3). None of the patients in either groups had incomplete or failed block. The mean heart rate and the mean arterial pressure during intra and post-operative period were comparable between both the group [Figs. 4 and 5]. The mean pain score (according to VAS pain score) of patients in both the group at 1 hour post-operatively was 0, at 2 h post-operatively mean pain score in Group R and RC were 1 and 0 ($p = 0.1544$). 8 h post-operatively it was 4.2 ± 2.3 and 1.6 ± 1.1 ($p < 0.0001$).

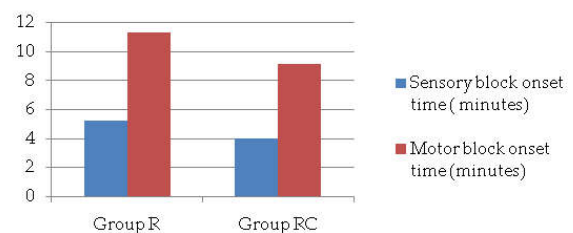


Fig. 1: Comparison of mean onset of sensory and motor block between Group R and Group RC

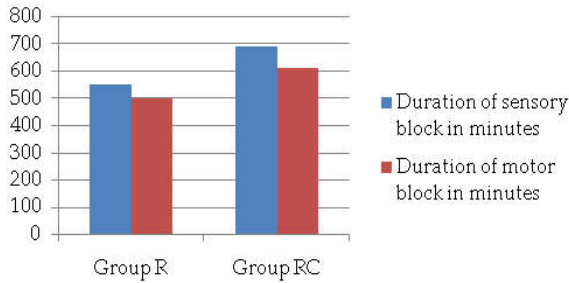


Fig. 2: Comparison of mean duration of sensory and motor block between group R and RC

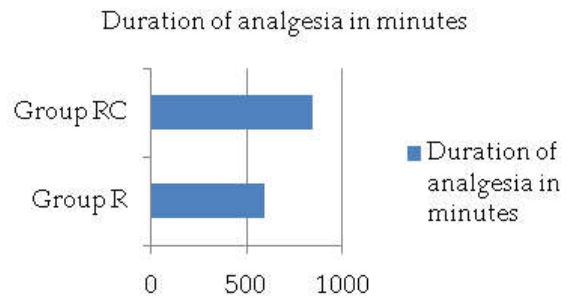


Fig. 3: Comparison of Mean duration of analgesia between Group R and Group RC

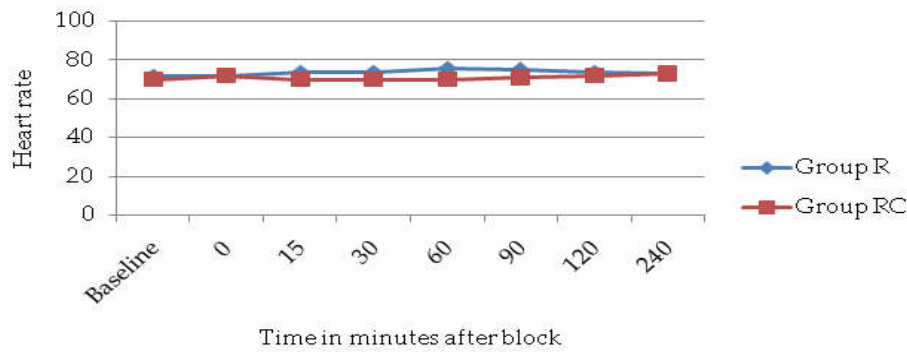


Fig. 4: Comparison of Mean Heart Rate

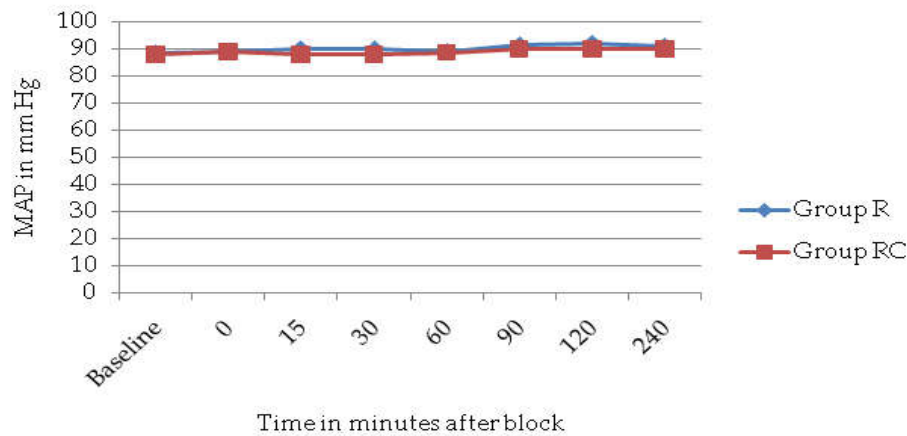


Fig. 5: Comparison of mean arterial pressure

Table 1: Demographics and vital parameters

Patient characteristics	Group R	Group RC	p value
Age in years	34.23 ± 8.20	34.66 ± 5.77	0.266
Weight (kg)	58.70 ± 4.62	58.27 ± 6.38	0.349
Heart rate (min)	75.59 ± 4.34	73.19 ± 5.54	0.239
SBP (mm Hg)	123.82 ± 23.13	122 ± 7.28	0.157
DBP (mm Hg)	71.59 ± 6.99	71.40 ± 8.08	0.447
MAP (mm Hg)	89.36 ± 6.16	88.53 ± 7.41	0.270

Values are mean ± Standard deviation, SBP- Systolic blood pressure, DBP- Diastolic blood pressure, MAP- Mean arterial pressure.

Discussion

Supraclavicular brachial plexus block popularly called as the “spinal of the arm” produces dense and reliable block with small volume of local anesthetic as it targets the compactly arranged trunks of brachial plexus [12,13]. It produces anesthesia of whole of the upper extremity except for the shoulder and upper arm.

In our study, the supraclavicular brachial plexus block was performed under ultrasound guidance which resulted in 100% success rate and zero percent incidences of the dreaded complications of the procedure such as intravascular injection and pneumothorax.

Unlike bupivacaine, ropivacaine is a pure S (-) enantiomer which confers it with less lipophilic property and decreased ability to penetrate large myelinated A β motor fibers, resulting in a comparatively lesser degree of motor blockade. As compared to bupivacaine, ropivacaine is having lesser propensity for central nervous system toxicity and cardiotoxicity [14,15,16,17]. So in our study we selected Ropivacaine instead of bupivacaine.

Clonidine, as an additive to local anesthetic solutions enhances both sensory and motor blockade of neuraxial and peripheral nerves [18]. Four postulated mechanisms for the action of clonidine in peripheral nerve blocks have been proposed. They are centrally mediated analgesia, α -2 adrenoceptor mediated vasoconstriction, anti-inflammatory action and direct action on peripheral nerve [10]. There is one more possible explanation which states that clonidine potentiates the sodium channel blocking property of local anesthetics by opening the potassium channels which results in hyperpolarization, a state where receptors do not respond to any stimuli [19].

In our study, addition of clonidine to ropivacaine resulted in significant reduction of onset time of both sensory and motor blockade. Supporting results to our study were obtained by Singh and Aggarwal [20]. and Patil KN and Singh ND [21].

Pöpping et al. did a meta-analysis of randomized trials and the results were heterogeneous. Clonidine got favourable results in 5 out of 11 for onset of sensory block and 2 out of 7 for onset of motor block [8].

In our study, Clonidine as an additive to ropivacaine significantly prolonged the duration of motor block, sensory block and duration of analgesia. This is supported by most of the studies performed [8,20,21,22,23].

In contrary to our study, few studies have demonstrated that clonidine as an adjuvant to local anesthetics in regional blocks, do not have any added advantages [24,25,26,27].

None of the participants from either groups observed any major adverse effects and were hemodynamically stable in the intra and post operative period, which can be attributed to the minimal dose of clonidine used in our study (0.5 μ g/kg), in contrast to other studies with higher dose range of clonidine [21,22,23].

Some studies like Pöpping et al., [8] Bernard and Macaire [28] and Büttner et al., [29] and have reported few adverse effects like bradycardia, hypotension and sedation.

Major advantage of our study was larger study population (n=100), as compared to many other studies which have used smaller numbers of study population [21,22,23].

In our study, we have injected lesser volume of drug (20 ml) as compared to other similar studies which have used larger volume (30 ml) [21,22,23].

Chief concern of our study is that even though prolongation of motor blockade by clonidine is beneficial for long duration surgeries, it may be detrimental in daycare surgeries where early mobilization is necessary.

Conclusion

The results of this study advocates usage of clonidine at lower dose (0.5 μ g/kg) as an adjuvant to 0.75% ropivacaine significantly enhances the quality of ultrasound guided supraclavicular brachial plexus block by faster onset of both sensory and motor block, prolonged duration of sensory and motor block and enhanced postoperative analgesia, without any adverse effects.

Key messages

Clonidine used as an additive to ropivacaine in ultrasound guided supraclavicular brachial plexus block enhances the onset and prolongs postoperative analgesia.

Financial support and sponsorship: Nil.

Conflicts of interest: There are no conflicts of interest.

References

- Murphy Damien B, McCartney Colin JL, Chan Vincent WS. Novel analgesic adjuvants for brachial plexus block: A systemic review. *Anesth Analg* 2000;90:1122-8.
- Sahu D, Sahu A. Lateral approach for supraclavicular brachial plexus block. *Indian J Anaesth*. 2010; 54:215-8.
- Kuthiala G, Chaudhary G. Ropivacaine: A review of its pharmacology and clinical use. *Indian J Anaesth* 2011;55:104-10.
- Akerman B, Hellberg IB, Trossvik C. Primary evaluation of the local anaesthetic properties of the amino amide agent ropivacaine (LEA 103). *Acta Anaesthesiol Scand*. 1988;32:571-8.
- Kim MH, Lee YM. Intrathecal midazolam increases the analgesic effects of spinal blockade with bupivacaine in patients undergoing haemorrhoidectomy. *Br J Anaesth*. 2001;86:77-9.
- Bajwa SJ, Bajwa SK, Kaur J, Singh G, Arora V, Gupta S, et al. Dexmedetomidine and clonidine in epidural anaesthesia: A comparative evaluation. *Indian J Anaesth*. 2011;55:116-21.
- Saravana Babu M, Verma AK, Agarwal A, Tyagi CM, Upadhyay M, Tripathi S. A comparative study in the post-operative spine surgeries: Epidural ropivacaine with dexmedetomidine and ropivacaine with clonidine for post-operative analgesia. *Indian J Anaesth*. 2013;57:371-6.
- Pöpping DM, Elia N, Marret E, Wenk M, Tramèr MR. Clonidine as an adjuvant to local anesthetics for peripheral nerve and plexus blocks: A meta-analysis of randomized trials. *Anesthesiology*. 2009;111:406-15.
- Khasar SG, Green PG, Chou B, Levine JD. Peripheral nociceptive effects of alpha 2-adrenergic receptor agonists in the rat. *Neuroscience*. 1995;66:427-32.
- Brummett CM, Norat MA, Palmisano JM, Lydic R. Perineural administration of dexmedetomidine in combination with bupivacaine enhances sensory and motor blockade in sciatic nerve block without inducing neurotoxicity in rat. *Anesthesiology*. 2008;109:502-11.
- Liu SS, Ngeow J, John RS. Evidence basis for ultrasound-guided block characteristics: onset, quality, and duration. *Reg Anesth Pain Med*. 2010 Mar-Apr;35(2 Suppl):S26-35.
- Fischer HB. Brachial plexus anesthesia. In: Wildsmith JA, Armitage EN, McClure JH, editors. *Principles and Practice of Regional Anesthesia*. 3rd ed. London: Churchill Livingstone; 2003.p.193-204.
- Urmey WF. Upper extremity blocks. In: Brown DL, editor. *Regional Anaesthesia and Analgesia*. Ch. 16. Philadelphia: W B Saunders; 1996.pp.254-78.
- Klein SM, Greengrass RA, Steele SM, D'Ercole FJ, Speer KP, Gleason DH, et al. A comparison of 0.5% bupivacaine, 0.5% ropivacaine, and 0.75% ropivacaine for interscalene brachial plexus block. *Anesth Analg*. 1998;87:1316-9.
- Ray M, Mondal SK, Biswas A. Caudal analgesia in paediatric patients: Comparison between bupivacaine and ropivacaine. *Indian J Anaesth*. 2003;47:275-8.
- Concepcion M, Arthur GR, Steele SM, Bader AM, Covino BG. A new local anesthetic, ropivacaine. Its epidural effects in humans. *Anesth Analg*. 1990; 70:80-5.
- Scott DB, Lee A, Fagan D, Bowler GM, Bloomfield P, Lundh R. Acute toxicity of ropivacaine compared with that of bupivacaine. *Anesth Analg* 1989;69:563-9.
- El-Hennawy AM, Abd-Elwahab AM, Abd-Elmaksoud AM, El-Ozairy HS, Boullis SR. Addition of clonidine or dexmedetomidine to bupivacaine prolongs caudal analgesia in children. *Br J Anaesth*. 2009;103:268-74.
- Butterworth JF 5th, Strichartz GR. The alpha 2-adrenergic agonists clonidine and guanfacine produce tonic and phasic block of conduction in rat sciatic nerve fibers. *Anesth Analg*. 1993;76:295-301.
- Singh S, Aggarwal A. A randomized controlled double-blinded prospective study of the efficacy of clonidine added to bupivacaine as compared with bupivacaine alone used in supraclavicular brachial plexus block for upper limb surgeries. *Indian J Anaesth*. 2010;54:552-7.
- Patil KN, Singh ND. Clonidine as an adjuvant to ropivacaine-induced supraclavicular brachial plexus block for upper limb surgeries. *Journal of Anaesthesiology, Clinical Pharmacology*. 2015; 31(3):365-369.
- Ali QE, Manjunatha L, Amir SH, Jamil S, Quadir A. Efficacy of clonidine as an adjuvant to ropivacaine in supraclavicular brachial plexus block: A prospective study. *Indian J Anaesth*. 2014;58:709-13.
- Aasim SA, Reddy AS, K Kumer AK, Satya KS. Prospective Study of the Efficacy of Clonidine Added to Ropivacaine as Compared with Ropivacaine Alone in Supraclavicular Brachial Plexus Block. *Ann. Int. Med. Den. Res*. 2017;3(4):AN01-AN04.
- Culebras X, Van Gessel E, Hoffmeyer P, Gamulin Z. Clonidine combined with a long acting local anesthetic does not prolong postoperative analgesia after brachial plexus block but does induce hemodynamic changes. *Anesth Analg* 2001;92:199-204.
- Duma A, Urbanek B, Sitzwohl C, Kreiger A, Zimpfer M, Kapral S. Clonidine as an adjuvant to local anaesthetic axillary brachial plexus block: A randomized, controlled study. *Br J Anaesth*. 2005;94:112-6.

26. Erlacher W, Schuschnig C, Orlicek F, Marhofer P, Koinig H, Kapral S. The effects of clonidine on ropivacaine 0.75% in axillary perivascular brachial plexus block. *Acta Anaesthesiol Scand.* 2000;44:53-7.
 27. Pinto Neto W, Issy AM, Sakata RK. A comparative study between bupivacaine and clonidine associated with bupivacaine in cervical plexus block for carotid endarterectomy. *Rev Bras Anesthesiol.* 2009;59:387-95.
 28. Bernard JM, Macaire P. Dose-range effects of clonidine added to lidocaine for brachial plexus block. *Anesthesiology.* 1997;87:277-84.
 29. Büttner J, Ott B, Klose R. The effect of adding clonidine to mepivacaine. Axillary brachial plexus blockade. *Anaesthesist.* 1992;41:548-54.
-